

Short communication:

Posterior Reversible Encephalopathy Syndrome:dilemma in obstetric management

Sunita Mishra, Priyali Purandre, Priyanka Patidar, Ratna Thakur, Anupriya Gupta

Department of Obstetrics and Gynaecology, Sri Aurobindo Medical College and Post Graduate Institute, Indore, Madhya Pradesh, India

Corresponding author : Dr Sunita Mishra

Department of Obstetrics and Gynaecology

Sri Aurobindo Medical College and Post Graduate Institute

Indore Ujjain Highway, Indore, India

Abstract:

Background; Posterior reversible encephalopathy syndrome (PRES) is a rare clinico-neuroradiological entity of sudden onset that can be characterized by headache, vomiting, altered mental status, blurred vision and seizures as well as images suggesting white-gray matter edema involving in most cases posterior regions of the central nervous system, as demonstrated by magnetic resonance image.

Case: Here we report the 3 cases that developed PRES as a complication of preeclampsia and eclampsia. 1st case had two episodes of convulsions before delivery and 5 convulsions after delivery at interval of half an hour. She has a high blood pressure(190/120mm Hg). MRI Brain was done which confirms the diagnosis of PRES. She was treated with Phenytoin and thereafter she recovered completely within 7 days without any neurological deficit. 2nd case was known case of sickle cell disease. She developed eclampsia during pregnancy and after 3 days of delivery she had two episodes of tonic clonic seizures. MRI Brain shows the presence of PRES. She recovered within 3 days after treated with Phenytoin. 3rd case had sudden loss of vision after 3rd day of delivery by LSCS. She also had a high blood pressure(130/90 mm Hg). MRI Brain shows patchy areas of diffusion restriction and vasogenic edema. Patient was treated with diuretics and hypertensive drugs. Patient became symptom free 3-4hrs after mannitol drip.

Conclusion: Preeclampsia and eclampsia is the major cause of PRES in pregnant women. therefore pregnant women with elevated blood pressure must counsel for the PRES and measure should be taken to maintain normal blood pressure.

Keywords: Preeclampsia, Posterior reversible encephalopathy syndrome, MRI, Pregnancy

Introduction:

The Posterior Reversible encephalopathy Syndrome (PRES) is a cliniconeuroradiologic entity. The global incidence of PRES is unknown. The only epidemiological data come from retrospective studies of patients seen between 1988 and 2008 [1,2]. PRES has been reported in patients aged 4 to 90 years, although most cases occur in young to middle-aged

adults, the mean age ranging across caseseries from 39 to 47 years [3].

It presents with rapid onset of symptoms of headache, seizures, visual disturbance and altered consciousness [4,5]. It is frequently but by no means for eternity associated with acute hypertension. If on time recognized and treated, the clinical syndrome usually resolves within a week [5,6] and the changes seen in

magnetic resonance imaging (MRI) resolve one to seven days [5,7].

PRES is an increasingly recognized disorder, with a wide clinical spectrum of both symptoms and triggers, and yet it remains poorly understood. Pre eclampsia is one of the important causes of PRES in pregnancy.

In this study we present three cases of PRES which came in unique pattern. All cases of PRES characterized the syndrome both clinically and radiologically in an attempt to better understand its pathophysiology. These diagnostic criteria are described in detail and management recommendations are given with an algorithm.

Case 1

A 21years primipara woman was referred to our hospital as a case of postpartum eclampsia in the state of coma with catheter in situ. History was taken from relatives, patient delivered live female baby and had two episodes of convulsions before delivery and 5 convulsions after delivery at interval of half an hour. She became unconscious after 8 hours of delivery. She was immunized with 2 doses of tetanus toxoid. No relevant past medical or surgical illness.

On examination patient's general condition was poor, unconscious responding to painful stimuli, pulse was 120/min, blood pressure was 190/120mmHg, respiratory rate was 18/min, chest was clear, CVS was S1S2+, no murmur, uterus was well contracted and bleeding per vagina was within normal limits. Planter reflex was normal and both pupils were equal & reactive to light. Fundus examination showed the presence of arteriolar attenuation. All other investigations were within normal limits except high urine albumin.

Patient treated with MgSO₄ (Pritchard regimen) and labetalol infusion till blood pressure 140/90 mmHg,

urine output were 600ml and higher antibiotics was started. Next day patient was conscious but disoriented, unable to move all her limbs. MRI brain was done which shows near symmetrical areas of abnormal intensity in bilateral high frontal and high parietal region with patchy areas of diffusion restriction and remaining areas of vasogenic edema [figure 1]. In the given clinical situation these changes are likely to represent PRES. Patient was immediately treated with antiepileptic drugs (Phenytoin (800mg) I/V in 100ml of Normal Saline followed by 100mg thrice in a day through infusion) and osmotic diuretic (Mannitol 100mg thrice in a day), and antihypertensive drugs. Patient responded to the treatment and recovered completely within 7 days without any neurological deficit. Patient was discharged on 8th day with advice to continue antihypertensive drugs and antiepileptic drug. She came for follow up after 7 days when she was advised to continue antihypertensive and stop antiepileptic drug.

Case 2:

A 25 year old lady having 36 week of pregnancy and known case of sickle cell anemia was referred to our hospital with complaints of bleeding per vagina. There was no past medical or surgical illness.

We reviewed the clinical inpatient and outpatient records of patient. General condition was average, afebrile, pulse was 84/min, blood pressure was 160/100mmHg, chest was clear, CVS was S1S2+ and no murmur.

Lower section caesarian section was taken immediately for fetal distress & MgSO₄ was given. Two units of whole blood were transfused. On post operative day 3, she had 2 episodes of generalized tonic clonic seizures. MRI was done which reveals edematous gyri and gyriform hyperintense in bilateral

cerebral hemispheres in bilateral posterior temporal parietal occipital and in the high posterior parietal & frontal cortex[figure 2]. These MR findings are suggestive of PRES. Patient was shifted on anti-epileptic drug (phenytoin 800mg in 100ml of normal saline (loading dose) followed by 100mg 8hrly), Calcium Channel blocker, and 3rd generation cephalosporin. She recovered within 3 days and rest of her post-operative period was uneventful.

Case 3: a 35 year old lady with G2P1L1 with 38 weeks oblique lie, and previous LSCS came to OPD with a single reading of raised B.P on admission (130/90 mmHg). No relevant past medical or surgical illness.

On examination general condition was fair, conscious responded well to place and person. Pulse was 84/min, regular, B.P was 130/90mmHg, RR was 20/min, afebrile, chest was clear; CVS was S1S2+, and no murmur. Per Abdomen examinations were as follows uterus was of term size, oblique lie, transverse scar

was present, relaxed. Fetal heart sound was 146 b/min and regular. Per vaginal examination revealed closed Os.

All other investigations were within normal limits. Bed side albumin was nil. She was normotensive throughout her antenatal period except on admission, the single reading was high. Elective LSCS was done. On post operative day 3, patient complained with sudden loss of vision. on examination planter reflex was found normal and pupils were reactive to light. MRI brain was done which shows near symmetrical areas of abnormal intensity in bilateral high frontal & high parietal region with patchy areas of diffusion restriction and remaining areas of vasogenic edema. In the given clinical situation these changes are likely to represent PRES. Patient was treated with osmotic diuretics infusion though infusion and antihypertensive drugs. Patient became symptom free 3-4hrs after mannitol drip & rest her postoperative period was uneventful.

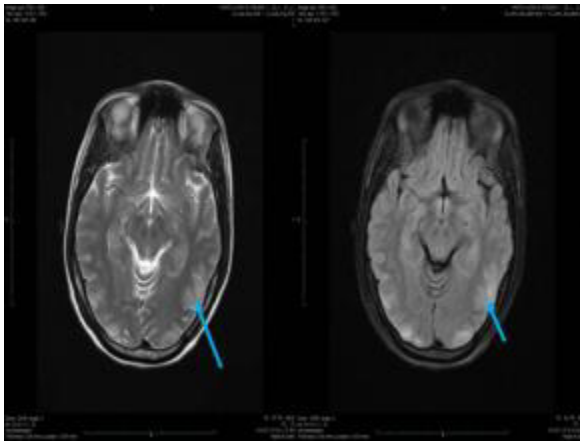


Figure 1: Axial FLAIR and T2 images near symmetrical areas of abnormal intensity in bilateral parieto-occipital region

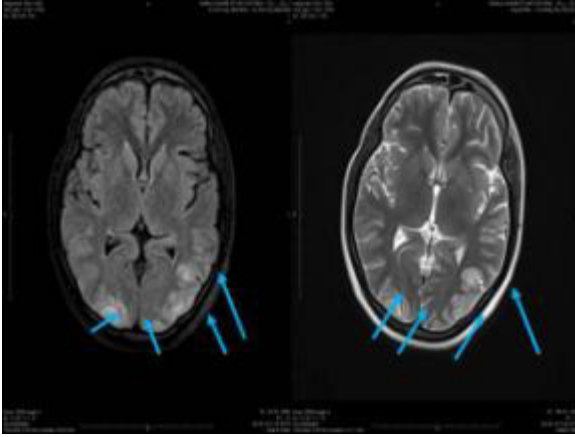

Figure 2: Axial FLAIR and T2 images show near symmetrical hyperintense areas of abnormal signal intensity in bilateral Parieto occipital Region

Discussion

In this clinical series, we found many of the classic etiologies and predisposing factors known to be associated with PRES, including abrupt hypertension, preeclampsia or eclampsia. The most common clinical presentations were new-onset seizures, encephalopathy, headache, and visual disturbances. Brain MRIs reviewed independently by neuroradiologists revealed the parieto-occipital head region to be the region most consistently involved, followed by the frontal lobe, temporal lobe, and cerebellum.

Cases of PRES have been widely reported since its first description and various factors such as etiology have been identified; however, numerous aspects regarding the pathogenesis of this entity are yet to be elucidated. Due to the vague, non-specific clinical scenario developed in patients with PRES, in order to establish early diagnosis of this condition, it is important to be cognizant of this entity as well as the possible causative factors involved on each case. The certain identification of this syndrome is achieved with MRI. The main features obtained with MRI are high density areas suggestive of CNS edema mostly

in the posterior white matter of the brain, although anterior structures and gray matter may also be involved. The treatment of PRES, as a secondary pathology, depends upon the determination of the underlying contributing condition; however, palliative therapy for symptoms that might worsen the outcome (e.g. seizures) must be provided, as well as strictly monitored BP control.

We found no correlation between clinical characteristics and the extent of vasogenic edema seen on brain imaging in PRES. This is consistent with previous findings,⁽⁸⁾ yet contradicts other reports suggesting that the extent of vasogenic edema may be inversely related to blood pressure at the time of symptom onset ⁽⁹⁾.

Status epilepticus is a not uncommon presentation of PRES. Its occurrence is not associated with the severity of radiologic edema, and most of these patients actually lack cortical involvement. Recognition that PRES may present with SE is important because, in addition to anticonvulsants, appropriate treatment requires identifying and treating the underlying cause of PRES.

This study is limited because the PRES patient population is underrepresented as a result of the organization of our medical center. In addition, the study shares the limitations of all retrospective studies, particularly in that the timing of follow-up imaging was not uniform. There may be a bias toward more benign cases because patients who died of acute critical illness had to be excluded to ensure reversibility. However, requiring proof of reversibility is actually a strength of our study because it preserves the homogeneity of the population. Additional strengths of the study are that it is one of the largest clinical series of PRES patients and that radiologic evaluations were completed by independent neuroradiologists blinded to the clinical details of the cases.

Conclusion

Although, the clinical presentation is non-specific, most patients have a suggestive combination of symptoms. MRI is crucial for diagnosis. Early recognition and resolution of the underlying cause is the keystone of the management. Persistence of the cause carries a risk of ischaemia, bleeding, and death. Atypical presentation and varied time of onset. Patients routinely counseled about S/S of pre-eclampsia. Post partum counseling should also include warning signs of persistent headache, Nausea/Vomiting, visual changes etc. If seizures & B.P. are not appropriately controlled, permanent neurological defects & even death can occur. It involves a multidisciplinary approach in the diagnosis as well as management.

Declaration of interest: The authors report no conflicts of interest. The authors alone are responsible for the content and writing of the paper.

References

1. Casey SO, Sampaio RC, Michel E, Truwit CL. Posterior reversible encephalopathy syndrome: utility of fluid-attenuated inversion recovery MR imaging in the detection of cortical and subcortical lesions. *Am J Neuroradiol* 2000; 21: 1199–1206.
2. Burnett MM, Hess CP, Roberts JP, Bass NM, Douglas VC, Josephson SA. Presentation of reversible posterior leukoencephalopathy syndrome in patients on calcineurin inhibitors. *Clin Neurol Neurosurg* 2010; 112: 886–889
3. Mishra S, Bhat R, Sudeep K, Nagappa M, Swain A, Badhe A. PRES (Posterior Reversible Encephalopathy Syndrome) and Eclampsia. *The Internet Journal of Neurology*. 2008; 121-4.
4. McKinney AM, Short J, Truwit CL, McKinney ZJ, Kozak OS, SantaCruz KS, et al. Posterior reversible encephalopathy syndrome: incidence of atypical regions of involvement and imaging findings. *Am J Roentgenol* 2007; 189:904–12
5. Roth C, Ferbert A. The posterior reversible encephalopathy syndrome: what's certain, what's new? *Pract Neurol* 2011; 11:136–44
6. Hinchey J, Chaves C, Appignani B, Breen J, Pao L, Wang A, et al. A reversible posterior leukoencephalopathy syndrome. *N Engl J Med* 1996; 334:494–500

7. Fugate JE, Claassen DO, Cloft HJ, Kallmes DF, Kozak OS, Rabinstein AA. Posterior reversible encephalopathy syndrome: associated clinical and radiologic findings. *Mayo ClinProc* 2010; 85:427–32
8. Mueller-Mang C, Mang T, Pirker A, Klein K, Prchla C, Prayer D.. Posterior reversible encephalopathy syndrome: do predisposing risk factors make a difference in MRI appearance? *Neuroradiology*. 2009;51(6):373-383.
9. Bartynski WS, Boardman JF, Zeigler ZR, Shaddock RK, Lister J. Posterior reversible encephalopathy syndrome in infection, sepsis, and shock. *Am J Neuroradiol*. 2006;27(10):2179-2190.